The effect of ankle immobilization and mechanical loading on tendon healing after Achilles tendon repair surgery

Mao Nie[1], Xinyi Kang[1], Xiang-Hua Deng, Keyu Wei[1], Yuexi Mou[1], Rongrong Wang[1], Xianding Sun[1]
[1]Joint surgery

INTRODUCTION:

Achilles tendon ruptures are common sports injuries typically treated with surgical repair. However, some studies indicate that nonsurgical methods can also lead to effective healing. Crucially, immobilizing the ankle in a plantar flexion position with an external fixator reduces tension on the tendon and aids recovery. The optimal duration for external fixation remains a topic of debate due to a lack of consensus and limited research. To investigate this, we developed a miniature external fixator for small animal ankle joints and used a mouse model to simulate acute complete Achilles tendon rupture. Our study evaluated treatment effectiveness through biomechanical, histological, and molecular assessments, focusing on the effects of fixation duration on tendon repair, function, and healing mechanisms. The goal is to establish a scientific foundation for determining the optimal duration of external fixation in clinical settings.

METHODS:

This study involved 85 male C57BL/6 mice, aged 12 weeks, which underwent right Achilles tendon transection and Kessler suture repair under anesthesia. The mice were divided into five groups based on the duration of ankle joint immobilization: 1 week, 2 weeks, 3 weeks, 4 weeks, and a control group with no immobilization (Figure 1). The immobilized groups were kept at a 160° plantar flexion using a specific external fixator, while controls had unrestricted movement. All mice were euthanized four weeks post-surgery for biomechanical testing, histological examination, immunohistochemical analysis, and quantitative PCR (qPCR) to assess tendon healing.

RESULTS:

A biomechanical analysis conducted four weeks postoperatively revealed that the group immobilized for 3 weeks had superior mechanical properties, with a failure load of 12.32 ± 0.94 N and stiffness of 5.69 ± 1.76 N/mm, although this difference was not statistically significant compared to the 2-week (failure load: 12.09 ± 0.89 N; stiffness: 5.64 ± 1.42 N/mm) and 4-week groups (failure load: 11.87 ± 0.91 N; stiffness: 5.26 ± 1.62 N/mm). Measurements at the 0-week mark showed significantly lower values, indicating inadequate tendon healing without mechanical restraint ($p < 0.01$, Figure 1). Histological evaluations showed better tendon repair and denser collagen fibers in the 2-week and 3-week groups (Figure 2). Immunohistochemical analysis revealed increased CD34 expression in the 0-week group, indicating active angiogenesis, while the 2-week and 3-week groups showed greater staining for COL1A1 and TNMD, reflecting tissue maturity. qRT-PCR results indicated higher levels of tendon repair-related genes in the 2-week and 3-week groups. The no-immobilization group had upregulated matrix-degrading enzymes (Mmp13) and pro-inflammatory markers (Il-6), suggesting prolonged inflammation. The 3-week group exhibited the lowest level of Fgf2, indicating a more stable tendon environment (Figure 3).

DISCUSSION AND CONCLUSION:

After Achilles tendon injury repair, non-weight-bearing ankle immobilization for a set period can promote healing and strengthen the tendon. However, prolonged immobilization may weaken the tendon due to a lack of mechanical loading stimulation. Additionally, failing to use external fixation can significantly impair the healing process. The findings of this study provide a significant experimental reference for the application of short-term ankle immobilization following clinical repair of the Achilles tendon.

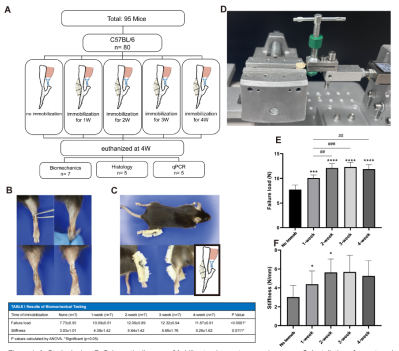

Table 2 Results of Biomechanical Testing

Time of immobilization	None (n=7)	1-week (n=7)	2-week (n=7)	3-week (n=7)	4-week (n=7)	P Value
Failure load	7.73±0.93	10.09±0.81	12.09±0.89	12.32±0.94	11.87±0.91	<0.0001*
Stiffness	3.35±1.51	4.38±1.42	5.64±1.42	5.69±1.76	5.26±1.62	0.0117*

P values calculated by ANOVA. *Significant (p<0.05).

Figure 1: A. Study design. B. Schematic diagram of Achilles tendon rupture repair surgery. C. Installation of an external fixator on the mouse's ankle joint. D. Test apparatus. E. Failure load (n=7). F. Stiffness (n=7). * Indicates the difference between each immobilization group and the non-immobilization group, and # indicates the statistical difference between the immobilization groups. Significance level: no difference ($p > 0.05$), * or # $p < 0.01$, *** or ### $p < 0.001$, **** or #### $p < 0.0001$. Values are means, and error bars indicate standard deviations.

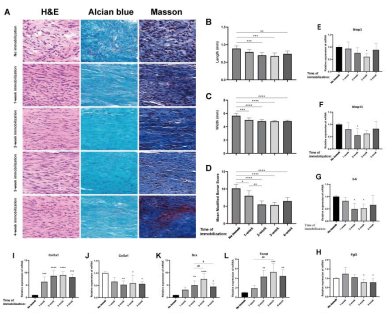

Figure 2: Evaluation of Achilles Tendon Healing at 4 Weeks Post-Surgery (n=5): A. Images of histological specimens of Achilles tendons analyzed using H&E, Alcian blue, and Masson staining under polarized microscopy. B. Quantification of tendon width. C. Quantification of tendon length. D. Modified Bonar score indicating histological integrity. E-L. qPCR analyses for Mmp3 (E), Mmp13 (F), Il-6 (G), Fgf2 (H), Col1a1 (I), Col3a1 (J), Scx (K), and Tnmd (L). * Indicates the difference between each immobilization group and the non-immobilization group. Data are presented as mean ± SD, with significance indicated by * $p < 0.01$, *** $p < 0.001$, and **** $p < 0.0001$.

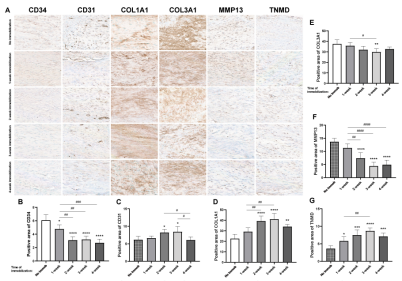

Figure 3: Immunohistochemical Staining and Semi-Quantitative Analysis of Tendon Tissue (n=5): A) Staining results for CD34, CD31, COL1A1, COL3A1, MMP13, and TNMD across five groups.
B-G) Quantification of staining for CD34 (B), CD31 (C), COL1A1 (D), COL3A1 (E), MMP13 (F), and TNMD (G) is shown. * Indicates the difference between each immobilization group and the non-immobilization group. Data are expressed as means ± standard deviation (SD), with significance indicated as follows: * $p < 0.05$, ** $p < 0.01$, *** $p < 0.001$, **** $p < 0.0001$.