Diagnostic Arthroscopy Is Useful in Identifying Patellofemoral Chondral Lesions Missed by MRI in Pediatric Patients Undergoing MPFLR

Romir P. Parmar, Amy Elizabeth Keane, Sailesh Tummala, Eugenia Lin, Neeraj Vij, Heather Menzer, Jeffrey M Vaughn

INTRODUCTION: Patellofemoral dislocations are often associated with chondral injuries. In adults, diagnostic arthroscopy (DA) has identified chondral injuries in up to one-third of cases where Magnetic Resonance Imaging (MRI) was negative. However, the value of DA in detecting cartilage injuries in pediatric patients undergoing medial patellofemoral ligament reconstruction (MPFLR) has not been well studied. This study aimed to evaluate the utility of DA in diagnosing cartilaginous injuries in pediatric patients undergoing MPFLR with negative preoperative MRI findings. A secondary objective was to compare postoperative outcomes between patients with and without chondral injury findings on DA.

METHODS: A retrospective review of patients aged 0-18 who underwent combined MPFLR and DA from 2015 to 2023 at a single institution was conducted. Exclusion criteria included revision MPFLR, tibial tubercle osteotomy, multi-ligament reconstructions, and prior meniscal injury. MRI and DA reports were reviewed for chondral findings. Patients were classified into three groups: +MRI/+DA, -MRI/+DA, and -MRI/-DA. Subgroup analysis was performed within the -MRI/+DA group to compare outcomes in the immediate postoperative recovery period between those who underwent a chondroplasty versus those who did not.

RESULTS: Of the 155 patients included, follow-up averaged 7.8 ± 8.2 months. Among 89 patients with negative MRI findings, 39 (43.8%) had chondral injuries detected on DA. Targeted treatment was performed in 22 (56.4%) of these patients, a lower rate than in those with positive MRI findings (80.3%, P=0.02). No significant differences in knee flexion were observed at 2 weeks postoperatively: +MRI/+DA (77.9° ± 23.0°), -MRI/+DA (66.5° ± 30.2°), and -MRI/-DA (73.3° ± 30.0°) (P=0.14). Similarly, no significant differences were found at 12 weeks: +MRI/+DA (135.3° ± 13.0°), -MRI/+DA (127.8° ± 21.0°), and -MRI/-DA (134.1° ± 13.4°) (P=0.10). Range of motion and complication rates were comparable across all groups (P>0.05). A subgroup analysis in the -MRI/+DA cohort comparing patients who underwent an arthroscopic procedure (n=22) to those who did not (n=17) showed no significant differences in range of motion or complication rates (P > 0.05).

DISCUSSION AND CONCLUSION: Diagnostic arthroscopy detected cartilaginous injuries in 43.8% of pediatric patients with negative preoperative MRI undergoing MPFLR. This highlights the diagnostic value of DA in identifying otherwise undetected injuries.

Figure 1: Patient Flow Chart

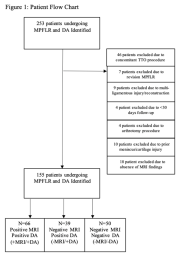

TABLE 1
Comparison of Patient Demographics

	+MRI/+DA	-MRI/+DA	-MRI/-DA	
Demographic	n=66	n=18	n=30	P
Age, y, mean ± SD	15.5 ± 1.8	16.8 ± 1.8	15.9 ± 1.8	0.06
BMI, kg/m^2	23.2 ± 5.3	26.3 ± 6.5	24.1 ± 6.3	0.16
Sex, n (%)				
Male	32 (48.5)	11 (28.2)	32 (24.0)	0.01
Female	34 (51.5)	28 (71.2)	88 (76.0)	0.01
Laterality, n (%)				
Right	34 (51.5)	13 (33.3)	25 (58.0)	0.16
Left	32 (48.5)	26 (66.7)	25 (58.0)	0.16
# of Patellar dislocations, mean ± SD	4.3 ± 5.0	3.2 ± 2.3	5.4 ± 4.4	0.48
Sport, n				
Basketball	8	4	8	0.70
Volleyball	8	1	5	0.25
Softball/baseball	5	3	6	0.13
Soccer	6	3	5	0.93
Dance/Gymnastics	7	12	5	0.01
Football	5	2	2	0.19
Martial Arts	4	2	2	0.58
Track	6	1	2	0.38
Miscellaneous	27	13	18	0.98

TABLE 2
Incidence of Chondral Injury Findings

	Negative MRI Report	Positive MRI report
Total	89	66
Positive on DA	39	66
Incidence	43.8%	100%

MRI: magnetic resonance imaging
DA: diagnostic arthroscopy

TABLE 3
Arthroscopic Findings and Arthroscopic Procedure completed to Treat Chondral Injury

	Positive MRI, Positive DA*	Negative MRI, Positive DA	
	n=66	n=39	P-value
Arthroscopic Findings			
Chondromalacia, n (%)*			
Grade I	14 (21.2)	15 (38.5)	0.09
Grade II	20 (30.3)	18 (46.2)	0.15
Grade III	8 (12.1)	6 (15.4)	0.86
Osteochondral lesion	15 (22.7)	0 (0)	<0.05
General chondral defect	9 (13.6)	0 (0)	0.04
Procedure Done	53 (80.3)	22 (56.4)	0.02
Shaving chondroplasty, n (%) **			
Medial patellar facet	20 (37.0)	10 (45.5)	0.71
Lateral femoral condyle	4 (7.4)	1 (4.5)	1.00
Lateral tibial plateau	2 (3.7)	1 (4.5)	1.00
Patella	13 (24.1)	10 (45.5)	0.13
Microfracture	6 (11.1)	0 (0)	0.24
Fixation	8 (14.8)	0 (0)	0.13

*** percentage of total number of patients**
**** percentage of those that had a procedure done**

TABLE 4
Comparison of Patient Outcomes

	Positive MRI, Positive DA*	Negative MRI, Positive DA	Negative MRI, Negative DA	
Outcome	n=66	n=39	n=50	P-value
Range of motion, deg, mean ± SD				
2-week flexion	77.9 ± 23.0	66.5 ± 30.2	73.3 ± 30.0	0.14
2-week extension	4.3 ± 8.7	2.8 ± 7.8	2.3 ± 5.0	0.41
12-week flexion	135.3 ± 13.0	127.8 ± 21.0	134.1 ± 13.4	0.10
12-week extension	1.8 ± 2.6	0.7 ± 3.7	0.4 ± 1.2	0.47
Complication rate, n (%)	13 (19.7)	10 (25.6)	13 (26.0)	0.67
Type of Complication, n				
Persistent pain	7	3	5	0.83
Subsequent dislocation	5	5	6	0.62
Revision/Hardware failure	0	2	1	0.18
Manipulation under anesthesia	1	0	1	0.69

TABLE 5
Sub-Group Analysis Comparing Patient Outcomes within Negative MRI, Positive DA Group

	Arthroscopic Procedure	No Arthroscopic Procedure	
Outcome	n=22	n=17	P-value
Range of motion, deg, mean ± SD			
2-week flexion	71.5 ± 25.0	60.3 ± 34.9	0.29
2-week extension	3.5 ± 9.3	1.9 ± 5.4	0.52
12 week flexion	129.4 ± 12.5	125.8 ± 28.8	0.68
12 week extension	1.3 ± 5.0	0.0 ± 0.0	0.33
Complications, n	5 (22.8)	5 (29.4)	0.92
Type of Complication, n			
Persistent pain	0	1	0.90
Subsequent dislocation	2	2	-
Hardware failure	0	1	0.90