

# Accuracy of Acetabular Cup Positioning using Patient-Specific Augmented Reality Guidance

Daniel C Sun<sup>1</sup>, William Murphy<sup>2</sup>, PATRICK M LANE, Stephen B Murphy<sup>3</sup>

<sup>1</sup>Tufts Medical Center, <sup>2</sup>Washington University in St. Louis, <sup>3</sup>CCAARS

## INTRODUCTION:

Malposition of the acetabular cup has been shown to contribute to postoperative complications following Total Hip Arthroplasty, including dislocations and revisions [1]. Surgeons have used many methods to achieve optimal placement of the acetabular cup, including preoperative planning, traditional navigation, robotics, and intraoperative radiography. More recently, an augmented reality guidance solution has been developed for implant positioning intraoperatively, allowing the surgeon to see 3D models including of the patient's pelvis and planned cup and cup handle orientation through AR glasses in and around the patient in real-time during surgery. The purpose of this study was to evaluate the accuracy of cup placement relative to the goal for surgeries performed using the augmented reality guidance platform.

## METHODS:

Twenty-five patients underwent CT based preoperative planning for use of the augmented reality guidance system. This includes 3D models of the patient's pelvis and femur and planned placement of the components. 3D holograms were created for display during surgery. At the time of the procedure, a smart mechanical navigation tool was docked to the patient with a tracking image located outside of the body in a predicted position. The holograms were then displayed in surgery on a headmounted device (Microsoft HoloLens 2) by anchoring and tracking the image. The surgeon then aligned the real cup handle as closely as possible to the projection of the cup handle. All cases were performed by the senior author.

After surgery, all patients underwent standing EOS biplanar imaging at their postoperative appointment [2]. These two images were used to calculate the achieved cup orientation. This was compared to the planned cup orientation.

## RESULTS:

The mean error in achieved vs planned operative anteversion of the acetabular cup was  $-1.5^\circ$  (SD:  $2.3^\circ$ , Min  $-6.0^\circ$ , Max  $2.0^\circ$ ), the mean error in operative inclination was  $-1.6^\circ$  (SD:  $2.6^\circ$ , Min  $-6.0^\circ$ , Max  $5.0^\circ$ ). The mean absolute error was  $2.1^\circ$  for operative anteversion, and  $2.4^\circ$  for operative inclination. Demographic information for patients is summarized in table 1.

## DISCUSSION AND CONCLUSION:

The augmented reality guided acetabular components were well placed with low mean error, and all cases within  $\pm 6$  degrees in both planes. Further studies may provide additional data on the accuracy of augmented reality guidance for accurate acetabular component placement in total hip arthroplasty.

## References:

[1] Techniques for Optimizing Acetabular Component Positioning in Total Hip Arthroplasty: Defining a Patient-Specific Functional Safe Zone. JE Feng, AA Anoushiravani, N Eftekhary, D Wiznia, R Schwarzkopf, JM Vigdorich; JBJS Reviews. 2019 Feb;7(2):e5. doi: 10.2106/JBJS.RVW.18.00049

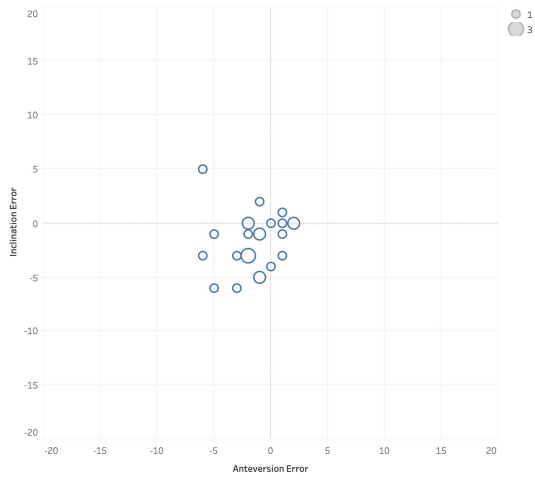
[2] Geometry of the EOS® Radiographic Scanner, B. N. Groisser, Department of Mechanical Engineering Technion-Israel Institute of Technology Haifa, Israel, [arXiv:1904.06711](https://arxiv.org/abs/1904.06711)

Legend:

**Figure 1:** Scatterplot of actual vs planned operative inclination and operative anteversion

**Table 1:** Results and demographics

Component placement from target (degrees)



Error Antev vs. Error Incl. Size shows count of Error Incl.

Table 1:

	<b>Accuracy</b>	<b>Degrees</b>	<b>Patient demographics</b>	
<b>Operative anteversion</b>	Mean error	-1.5	N	25
	SD error	2.3	Average age at surgery	60
	Max error	2.0	SD age at surgery	9.7
	Min error	-6.0	Min age at surgery	38
<b>Operative inclination</b>	Mean absolute error	2.1	Max age at surgery	76
	Mean error	-1.6	Male	15
	SD error	2.6	Female	10
	Max error	5.0	Male (%)	60%
	Min error	-6.0	Female (%)	40%
	Mean absolute error	2.3		